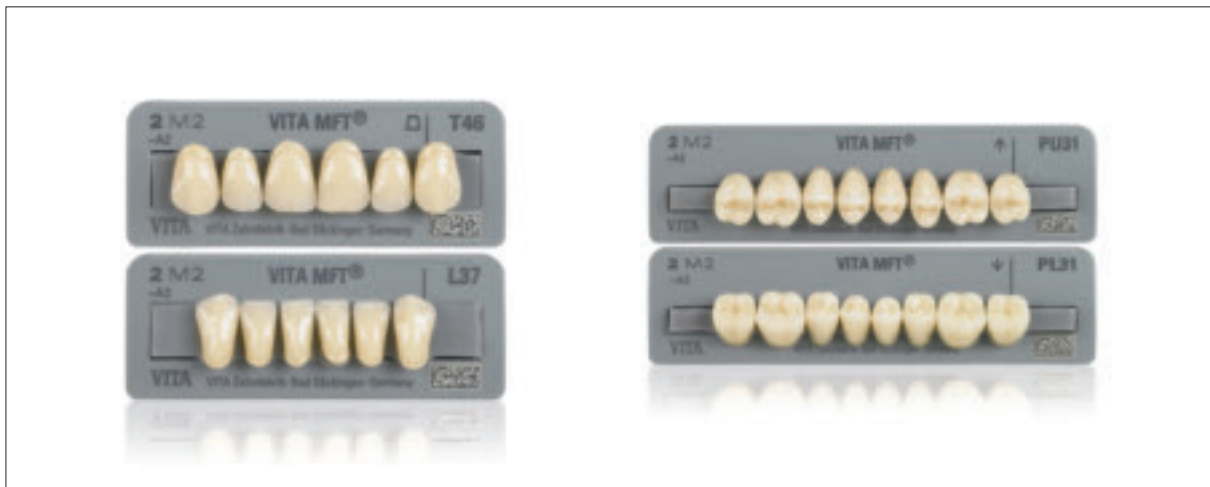

# VITA MFT®

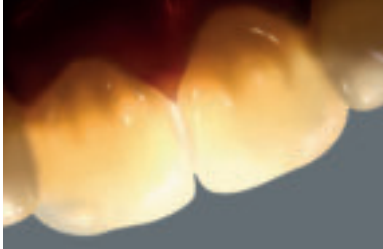Setup guide



VITA shade, VITA made.

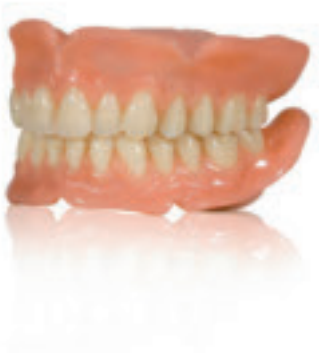**VITA**

## VITA MFT Anteriors - In harmony with nature

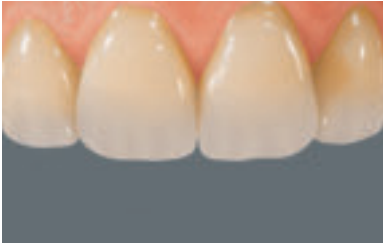
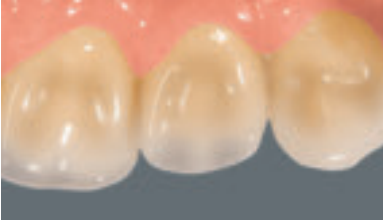
VITA Multi-Functional Teeth (MFT) offer a true-to-nature appearance, built up in three layers - particularly visible with the VITA MFT anteriors - and meet all the criteria of a quality restoration to satisfy the patient's needs :

- Opalescence, luminescence and translucence - with a perfectly matching natural-looking morphology and an individual mamelon structure - create a play of colors rich in nuances with a vivid light reflection behavior in every single tooth.
- A slightly convex design of the labial facettes helps enhance the lip contour and thus promotes dentofacial harmony.

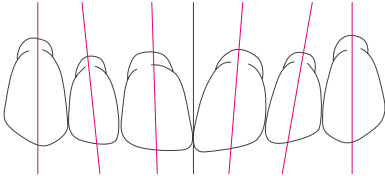


## VITA MFT Anteriors - In harmony with nature



- The nature-identical design of the palatal surfaces preserves every patient's phonetic skills and the tongue contact he/she is used to.
- As a further highlight, the whitish incisal margin supports the outstanding aesthetics of the VITA MFT anteriors.
- Slightly broadened tooth neck areas at anteriors and posteriors reduce the effort for a true-to-nature and age-specific design of the interdendum.

## Setup of the upper anteriors

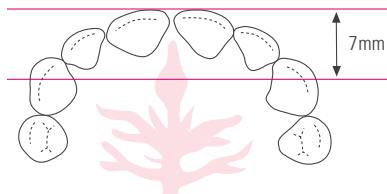


The following suggestions should be followed to ensure a natural appearance of the anterior setup:

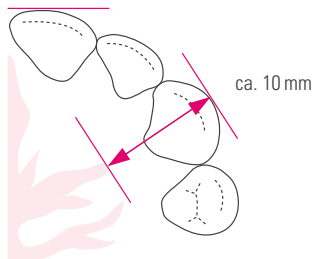
- The central incisors are upright.
- The cervical portion of the lateral incisors is inclined distally.
- The canines are tendentially upright, with the tooth neck inclined vestibularly.
- The incisal edges **of the upper central incisors** run parallel to, and are situated approximately +/- 1-2 mm above the occlusal plane.
- The incisal edges **of the upper lateral incisors** run parallel to, and do not touch the occlusal plane.
- The tips **of the canines** are situated approximately on the occlusal plane.

The teeth are mostly positioned, according to the atrophy of the upper jaw, in front of the alveolar ridge - with their labial surfaces over the vestibule.

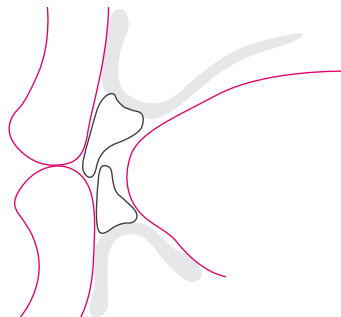
## Setup of the upper anteriors



In normal occlusion, the upper anteriors are positioned at a distance of approx. 7 mm in front of the centre of the incisal papilla.

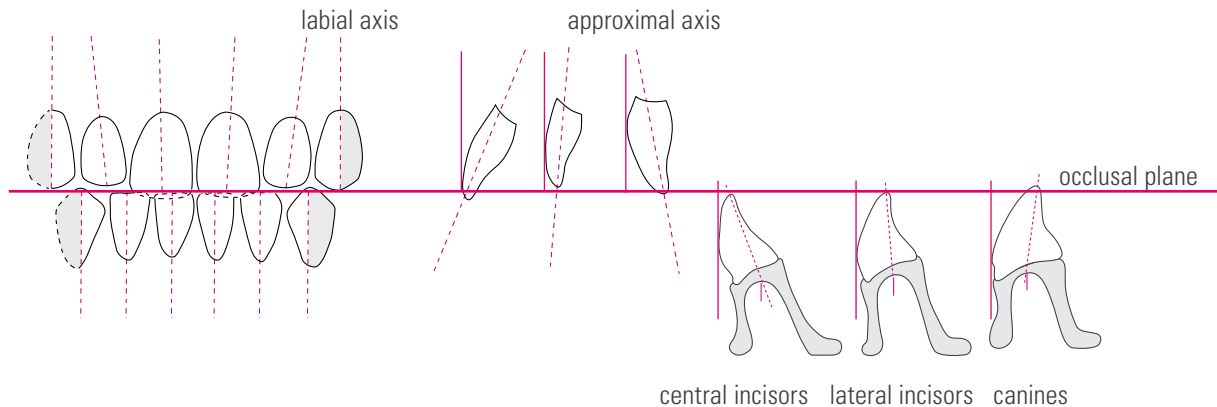


The labial surfaces of the upper anteriors provide support to the upper lip. The incisal edges of the central incisors ensure a harmonious lip contour.

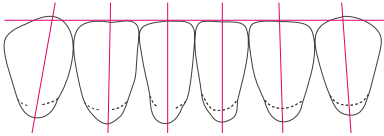


The tips of the two canines are positioned at a distance of approx. 10 mm from the end of the first pair of palatal rugae.

## Setup of the anteriors with reference to the occlusal plane



## Setup of the lower anteriors



The lower anterior setup should display the following characteristics:

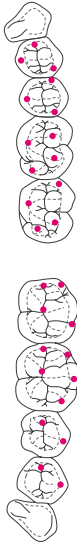

- The incisal edges of the lower incisors are level with and run parallel to the occlusal plane.
- The tips of the canines are situated slightly above the occlusal plane.

From the labial view:

- The central incisors are straight and upright.
- The lateral incisors show a slight mesial inclination.
- The canines are straight or show a slight mesial inclination.
- The distal facet of the canine points in the direction of the molars.

When positioning the tooth necks on the alveolar ridge, the following rule of thumb can be applied: the central incisors are on, the lateral incisors at and the canines outside of the lower alveolar ridge path.

## VITA MFT Posteriors – Highest productivity

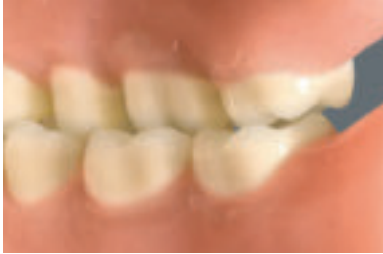

The VITA MFT design of occlusal surfaces is based on the innovative easy-centric principle, i.e. the surfaces are designed so that the perfect centric is reached almost automatically.

- Easy-centric ensures a professional as well as an economical setup of dentures including a safe occlusion on determination, offering production efficiency with results that address the patients' needs.
- Pre-abraded occlusal surfaces of the lower posteriors help minimize horizontal shear forces, thus supporting the ideal static alignment of the prosthesis. This is particularly important with implant supported prostheses.

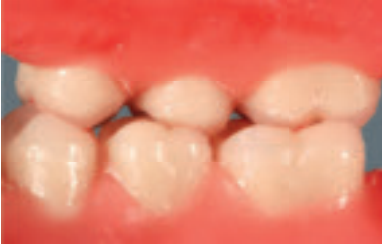

## VITA MFT Posteriors – Highest productivity



- The ideal design of upper posterior cusps lead to correct centric and provides optimum chewing comfort for the patient.
- Reduced ridge lap allows for a significant reduction of grinding work and enlarges the surface for safe bonding to the denture base material.

## Significance / benefits of lingualized occlusion in dental prosthetics



The main characteristic of lingualized occlusion is an optimal positional stability of a dental prosthesis.

In both static and dynamic occlusion, it is important to ensure that all occlusal forces, in close occlusal contact, are aligned towards the centre.

When setting up the teeth, the focus should be on the central palatal contact relationship.

# Significance / benefits of lingualized occlusion in dental prosthetics

## Good results regarding both medically and static occlusion:

- Prosthetic restorations are decisively improved when faced with difficult statics or when there is a strong divergence between conditions in the upper and lower jaw. This means that in the case of larger lower and smaller upper dental arches - which were often solved by setting up a crossbite - the teeth can be set up further buccally without compromising the stability of the prosthesis. This can also help avoid the build-up of pressure areas.
- Thanks to the axial direction of force, this concept prevents excessive strain on the rest area of the prosthesis, which is particularly beneficial in the case of implant prosthetics. This is mainly due to the fact that this offers protection to a great extent against horizontal shear forces.
- The greater accuracy in the positioning of the mastication elements in the so-called "neutral zone" (i.e. muscular balance) leads to better cheek contact of the teeth and noticeably more tongue space for the patient. This cheek contact prevents the formation of a food bolus in the vestibular area and helps horizontally stabilize the prosthesis.

# Significance / benefits of lingualized occlusion in dental prosthetics

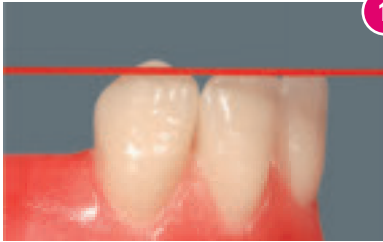
## For the patient this means:

- More tongue space resulting in greater comfort.
- Less biting of the cheek through reduction of buccal contacts.
- Alleviates pressure areas.
- Small, regulatory checking movements (Dr. Hildebrandt) with slight disclusion are possible.

## Benefits for the dental technician / laboratory:

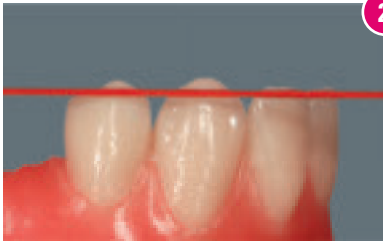
- Clear, unmistakable and reproducible contact relationships.
- Understandable and verifiable setup criteria.
- Time is saved by efficient and accurate setup procedures.

## Setup of the lower anteriors and the first premolar



1

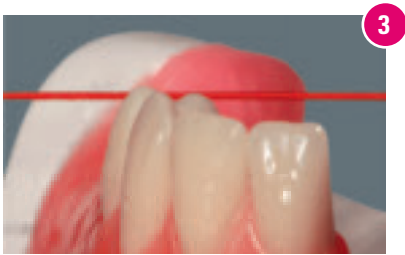The lower incisors are aligned to the occlusal plane with the labial surfaces pointing in the direction of the upper palatal ruga.  
The longitudinal axis of the canines is inclined at right angles to, and should be situated approximately 1 mm above, the occlusal plane.



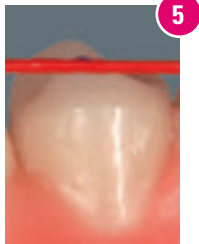
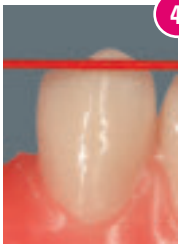2

The setup of the first lower premolar is identical to the canine. As a result, it is aligned at right angles to the occlusal plane.  
The mesial area of the buccal facet is above the occlusal plane, as is the canine; the distobuccal area follows the line of the occlusal plane.

## Checking the setup of the first lower premolar



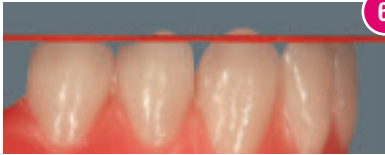
- The tooth axis is aligned at right angles to the occlusal plane.
- Fig. 3: the mesiobuccal area is situated above the occlusal plane.
- Fig. 4: the setup of the distobuccal area follows the line of the occlusal plane.
- Fig. 5: the lingual cusp tip is located in the area of the occlusal plane.



Please note: To achieve an optimal contact point relationship, the lingual cusp of the first lower premolar is given a functionally oriented design corresponding to its dominance.

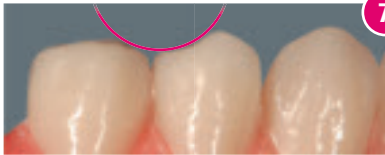
See also Figs. 16, 21, 23

## Setup of the second lower premolar



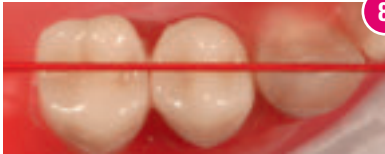6

The neck of the second lower premolar shows a slight distal inclination in comparison to the first premolar.



7

Mesially to the first premolar, the teeth should be set up with a harmonious rounded contour, which facilitates the correct functional setup of the first upper premolar. See also Fig. 19



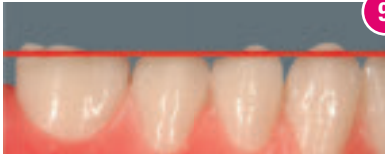8

The lingual cusp is also aligned to the occlusal plane.

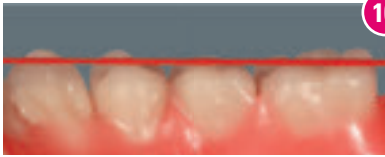
See also Figs. 10, 13

The setup follows an imaginary line which runs from the canine distal facet through the central fissures of the premolars and molars. See also Fig. 11

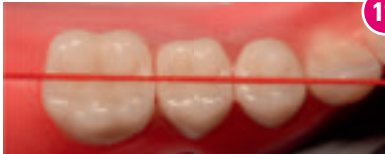## Setup of the first lower molar **without** the setup of the second lower molar



Following the setup pattern of the second premolar, the first molar is raised distally so that the distobuccal cusp reaches the level of the canine and the first premolar, i.e. it is situated approx. 1 mm above the occlusal plane: Fig. 9.



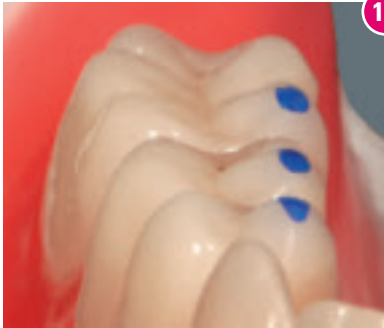The lingual cusps are aligned to the occlusal plane: Fig. 10  
See also Fig. 13



The setup follows an imaginary line which runs from the canine distal facet through the central fissures of the premolars and molars. Fig.11



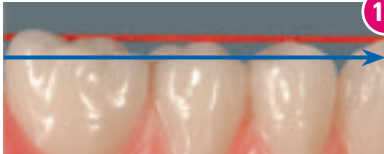
## Setup of the lower posteriors



12

**Aids for checking the setup (important: do not use contact points for this):**

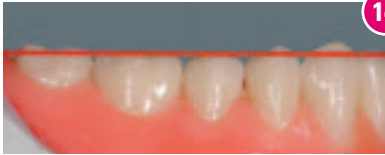In addition to using rubber thread, to help mark the lingual cusp tips of the lower VITA MFT posteriors (important: do not use contact points), it is very simple to verify the correct orientation of the posterior setup and the identical height of the posterior teeth with reference to the occlusal plane.



13

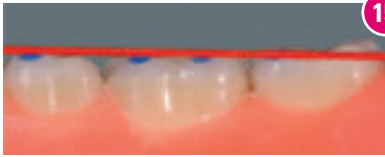This view clearly shows the cuspal progression of the setup from lingual to buccal, as well as from buccal to lingual. It shows that all cusps up to the buccal cusp of the first premolar and the distal cusps of the first molar are aligned to the occlusal plane.

## Setup of the first lower molar **with** the setup of the second lower molar



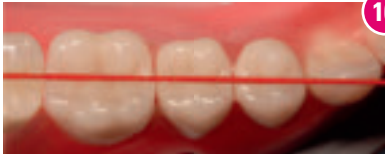14

In this case, continuing the trend of the second premolar, the first molar is set up flat (i.e. with its distobuccal cusp touching the occlusal plane).



15

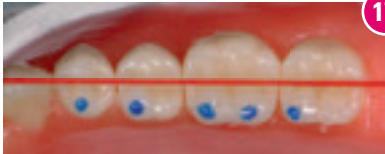The lingual cusps also in contact with the occlusal plane.



16

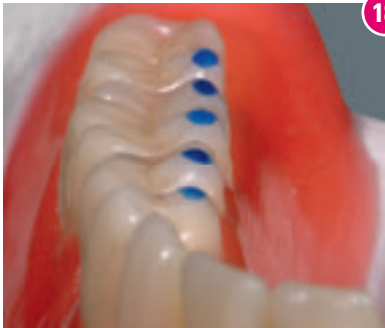The setup follows an imaginary line which runs from the distal facet of the canine through the central fissures of the premolars and molars.

## Setup of the lower posteriors



17

In addition to checking the setup using rubber thread, it is very simple to verify the correct orientation of the posterior setup with the help of the markings on the lingual cusp tips of the lower VITA MFT posteriors.



18

This perspective shows the straight lingual progression of the cusps from mesial to distal.

## Setup of the upper posteriors - first upper premolar

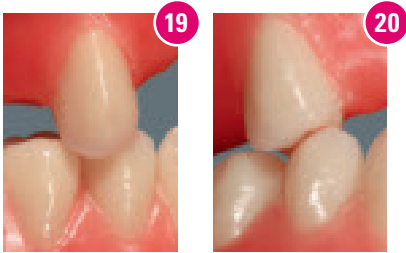


Fig. 19: The first upper premolar is positioned at right angles to the occlusal plane, resulting in a tooth-to-tooth relationship with its antagonist. See also Figs 4, 7

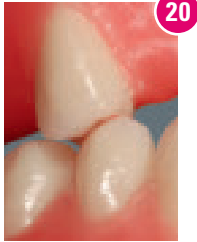
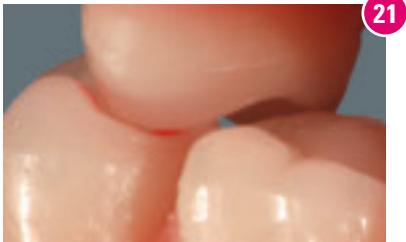
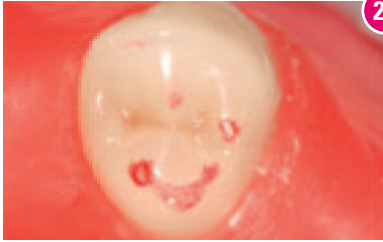
Fig. 20: The first upper premolar is set up slightly opened towards the buccal side, the first lower premolar has contact on the mesial marginal ridge in the area of the mesiocentral fossa of the first upper premolar.



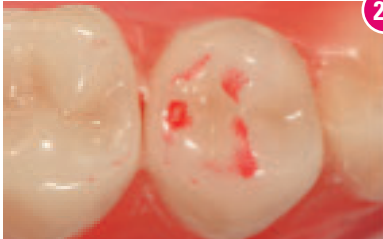
In order to improve the static occlusion, the first upper premolar achieves a secure contact relationship in the central fossa of the lower antagonist.

## First upper premolar: contact relationship



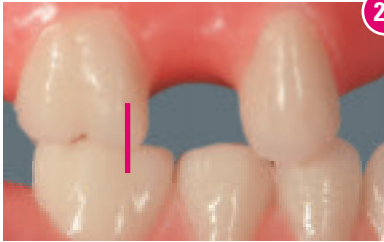The mutual contact relationship of the first premolars is clear, unmistakable and always reproducible:

The mesial marginal ridge of the palatal cusp in the upper jaw forms a clear mutual tripodization (three-point support) with the distolingual fossa of the lower premolar.



It is important to ensure sufficient buccal freedom. This is required in order to benefit from the free space in the molar area. See also Fig. 20

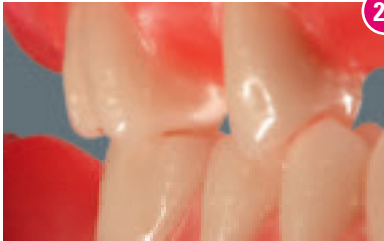## Setup of the first upper molar



24

On account of the reliable and unambiguous setup pattern of the teeth (highest number of reference points), it is advantageous to set up the first molar before the second premolar.

The first molar, like the premolars, is set up with a tooth-to-tooth relationship.



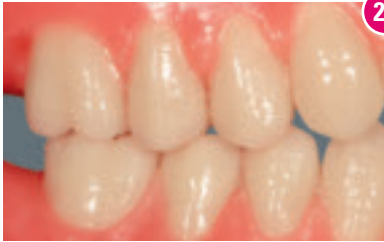25

Besides the centric palatal contact relationship, care should be taken to ensure sufficient buccal space.

A space of between 1 and 2 mm is generally required.

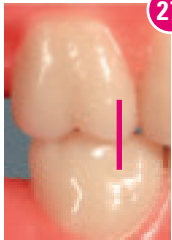
See also Figs. 26, 27, 28

## Setup of the second upper premolars

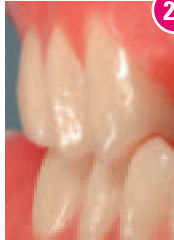


26

The second upper premolar is then set up in the remaining space. From a functional viewpoint, with a tooth-to-tooth relationship, and approximately at right angles to its antagonist in the lower jaw.



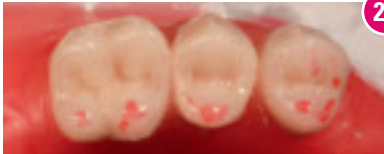27



28

The second upper premolar is also set up with buccal freedom. According to its size, this is positioned between the first premolar and the first molar. The goal is to achieve a harmonious transition, in which the free space is increased successively from the the first premolar to the last molar.

## Contact relationships of the upper to the lower posteriors

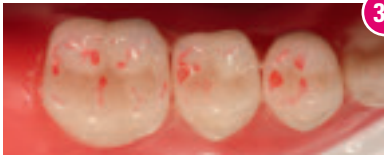

29

The contact relationship of the VITA MFT posterior tooth:

Fig. 29: The focus is mainly on the palatal support.

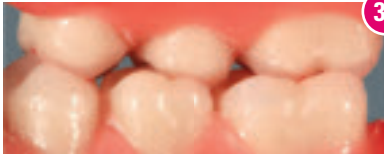
Fig. 30: The palatal cusps bite precisely into the fossae of the mandibular teeth.



30

This type of setup helps stabilize the restoration and at the same time allows for increased tongue space.

The forces hereby transferred to the mucosa and the underlying bone can be minimized. This generally proves beneficial to the denture-bed structures (i.e. protects these from undue strain) and can be a decisive factor regarding the survival rate of placed implants.

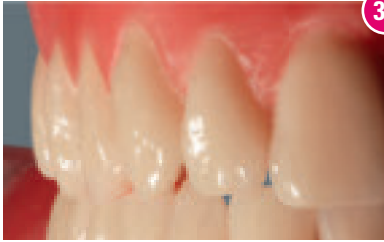

31

Fig. 31: The palatal view shows optimum intercuspation.

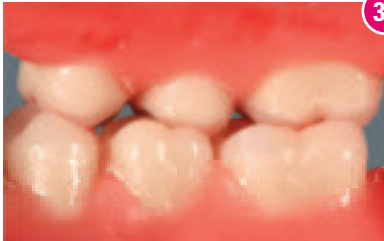

## The finished prosthesis



32

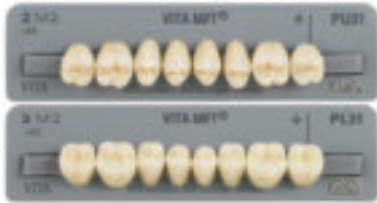The mesial, buccal and palatal view of the completed setup shows the connection between clear, reproducible function and esthetic harmony.



33

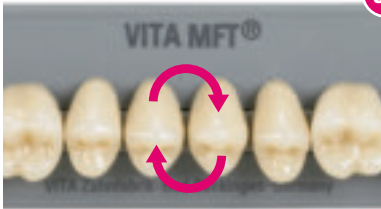The excellent (highly precise) palatal contact relationship is guaranteed through the consistent application of the lingual occlusion principles according to Prof. Dr. Gerber. At the same time, the requirements regarding the correct functional alignment of the teeth are fulfilled through a statically correct setup.

## Extended application possibilities



Especially the first upper premolar plays a key part in complete denture prosthetics.

Just like natural dentition, in addition to providing centric palatal support, it helps guide the mandible while sliding into the centric position.

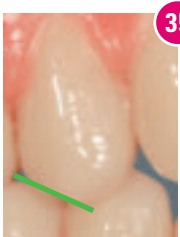

34

To make this guidance more active or more passive, the first upper premolar can be exchanged quadrant-wise prior to setting up.

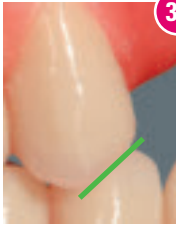
No change is made to the setup of the lower teeth. The centric contact relationship of the premolars remains virtually unchanged.

## Exchange 14/24



35

Tooth 14 straight from the teeth set



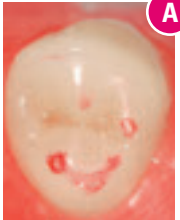
36

exchanged: tooth 24

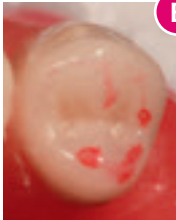As illustrated here, a further essential difference can be seen if tooth 14 is exchanged with tooth 24.

Fig. 35: The occlusal contact surface on the first premolar is clearly recognizable from the distobuccal view.

Fig. 36: When tooth 14 is replaced by tooth 24, this occlusal contact surface changes from distal to mesial. This increases the free space buccally around the centric position and strengthens the palatal contact relationship.



A

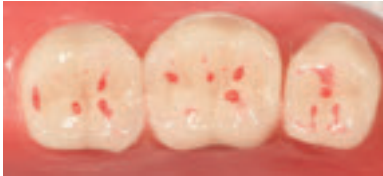

B

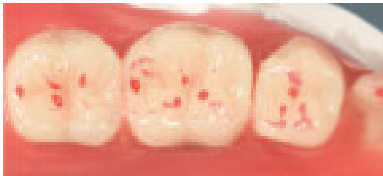
This makes virtually no difference to the alignment of the tooth axis or the tooth-to-tooth relationship.

Figs. A and B: The appearance of the contact relationship remains identical in its arrangement despite the substitution of the two teeth.

## Reliable achievement of the contact points

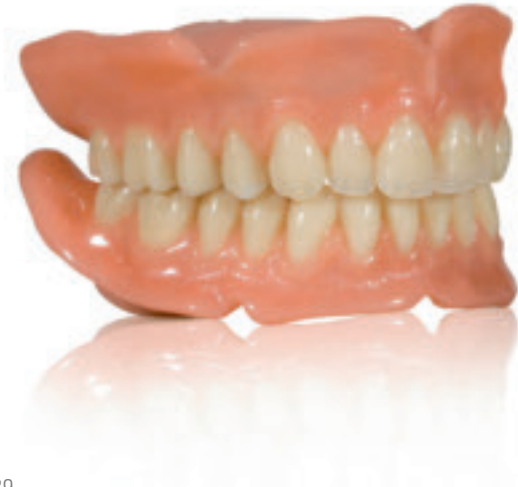

Defined centric occlusion with stable tripodization of the molars in the mesial, central and distal area of the lower fossa, highlights the multifunctionality of VITA MFT teeth.



In the case of a mesial shift, the tripodic function remains fully intact - this plays a decisive part in both the combined technique and implant prosthetics.

## The finished prosthesis

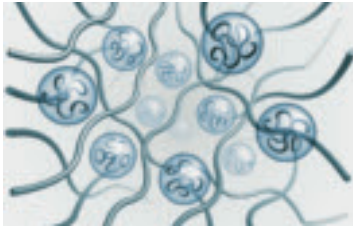


A finished restoration with **VITA MFT** T46, L37, PU31 and PL31.

### **Satisfied patients thanks to VITA MFT.**

The vivid impression of the teeth promotes a natural appearance and results in the patient's very rapid acceptance of the restoration. First-class material in the well-established VITA quality provides for maximum tissue compatibility and long restoration life.

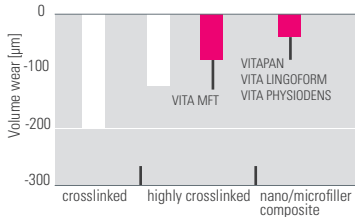
# VITA MFT – made of top-quality material



PMMA pearls

cross-linked PMMA

## Two-Body Wear Resistance<sup>1</sup>



<sup>1</sup>The results of Im-vitro wear resistance study of Universitätsklinikum Regensburg, Nov. 2009

## Excellent material quality and outstanding biocompatibility

is achieved through the entire tooth using a homogeneous, very dense cross-linked acrylic material throughout the entire tooth.

- good shade stability
- abrasion resistant
- tissue friendly
- plaque resistant
- splinter-free grinding
- excellent polishing properties
- perfect bonding to the denture base material
- free of residual monomers
- crack resistant

## Sources

Hofmann-Axthelm, Lexikon der Zahnmedizin

Hohmann-Hielscher, Lehrbuch der Zahntechnik, Quintessenz Verlag 2001

Stuck /Horn „Zahnaufstellung in der Totalprothetik“

Parsche E., Funktionslehre/Biomechanik Graz 2006

Gründler, H. /Stüttgen, U., Die Totalprothese, Verlag Neuer Merkur GmbH 1995

Linke u.a., 2001

Tschirch, 1966

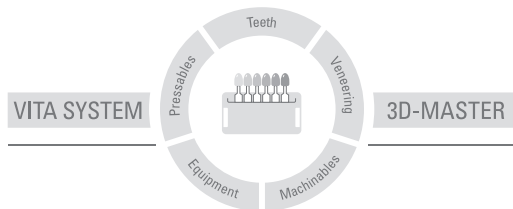
VITA, A Guide to Complete Denture Prosthetics, 2010

We would like to thank Mr. Karl-Heinz Körholz for his support in writing this setup guide.





This product group is available in the VITA SYSTEM 3D-MASTER and VITA classical A1 – D4 shades. Shade compatibility with all VITA 3D-MASTER and VITA classical materials is guaranteed. With the unique VITA SYSTEM 3D-MASTER, all natural tooth shades can be systematically determined and perfectly reproduced.



**Please note:** Our products should be used according to the working instructions. We cannot be held liable for damages resulting from incorrect handling or usage. The user is furthermore obliged to check the product before use with regard to its suitability for the intended area of applications. We cannot accept any liability if the product is used in conjunction with materials and equipment from other manufacturers which are not compatible or not authorized for use with our product. Furthermore, our liability for the correctness of this information is independent of the legal ground and, in as far as legally permissible, is limited to the invoiced value of the goods supplied excluding turnover tax. In particular, as far as legally permissible, we do not assume any liability for profit loss, for indirect damages, for consequential damages or for claims of third parties against the purchaser. Claims for damages based on fault liability (fault in making the contract, breach of contract, unlawful acts, etc.) can only be made in the case of intent or gross negligence.

The VITA Module Box is not necessarily a component of the product. Date of issue of this product information: 05.15  
VITA Zahnfabrik has been certified in accordance to the Medical Device Directive and the following products bear the CE mark: **CE**<sub>0124</sub>

**VITA MFT®**

# VITA

---

VITA Zahnfabrik H. Rauter GmbH & Co.KG

Spitalgasse 3 · D-79713 Bad Säckingen · Germany

Tel. +49(0)7761/562-0 · Fax +49(0)7761/562-299

Hotline: Tel. +49(0)7761/562-222 · Fax +49(0)7761/562-446

[www.vita-zahnfabrik.com](http://www.vita-zahnfabrik.com) · [info@vita-zahnfabrik.com](mailto:info@vita-zahnfabrik.com)

 [facebook.com/vita.zahnfabrik](https://facebook.com/vita.zahnfabrik)

© VITA Zahnfabrik H. Rauter GmbH & Co.KG